

# HASIL CEK\_Jurnal Haris 2- dikonversi

*by* Jurnal Haris 2-dikonversi Haris

---

**Submission date:** 12-Apr-2022 09:09AM (UTC+0700)

**Submission ID:** 1808387657

**File name:** Jurnal Haris 2-dikonversi.docx (1.47M)

**Word count:** 4632

**Character count:** 25981



## The Effectiveness Combination of Maggot with Commercial Feed on Growth, Structure of Intestine and Skeletal Muscle *Mutiara* Catfish

Haris Setiawan<sup>1\*</sup>, Ichsan Luqmana Indra Putra<sup>2</sup>, Ridwan Alfatah<sup>1</sup> and Akhmad Nizzar Nasikhudin<sup>1</sup>

<sup>1</sup>Laboratory of Animal Structure and Physiology, Program Study of Biology, Faculty of Applied Science and Technology, Universitas Ahmad Dahlan, Jl. Kapas 9, Semaki, Umbulharjo, Kota Yogyakarta, Daerah Istimewa Yogyakarta 55166, Indonesia

<sup>2</sup>Laboratory of Ecology and Systematic, Program Study of Biology, Faculty of Applied Science and Technology, Universitas Ahmad Dahlan, Jl. Kapas 9, Semaki, Umbulharjo, Kota Yogyakarta, Daerah Istimewa Yogyakarta 55166, Indonesia

\*Correspondence :  
haris.setiawan@bio.uad.ac.id

Received : 2021-03-23  
Accepted : 2021-09-27

Keywords :  
Intestine, Maggot, *Mutiara* catfish,  
Skeletal muscle

### Abstract

Maggot (Black soldier fly larvae) as an alternative source of protein on feed can increase fish productivity. The research aims to study maggot flour as an alternative source of protein in feed on the growth, the structure of the intestine organs, and skeletal muscles of *Mutiara* catfish (*Clarias gariepinus* Burchell, 1822). The research used 144 *Mutiara* catfish that were kept for 21 days. The research used a completely randomized design consisting of 4 groups, namely 0% maggot in feed (Control), 25% maggot in feed (P1), 50% maggot in feed (P2), 75% maggot in feed (P3). The parameters consist of the growth, the structure of the intestine, and the skeletal muscle of *Mutiara* catfish. Growth observations consist of measurements of the absolute length and weight of the fish. Intestine observations consisted of length and weight, as well as tissue structure consisting of villi height, crypt depth, villi/crypt ratio, and villi area. Skeletal muscle observations consist of muscle weight and tissue structure consisting of the diameter and area of muscle fibers. Data analysis was performed with a one-way ANOVA, followed by the Duncan test. The results showed that 75% maggot feed gave significant results on absolute weight, the structure of the intestine, and muscle organs compared to other treatments ( $P < 0.05$ ). The absolute length did not provide a significant difference between treatments ( $P > 0.05$ ). The conclusion shows that 75% maggot feed can be used as an alternative source of feed protein because it can increase the growth, structure of the intestine organs and skeletal muscles of the *Mutiara* catfish.

### INTRODUCTION

Catfish (*Clarias gariepinus* Burchell, 1822) is one of the cultivated fish species in freshwater cultivated in tropical regions such as Indonesia, Malaysia, Thailand, and

China. Catfish is a type of fish that is easy to maintain, has a very fast growth rate, but has a relatively affordable price in the market. One type of catfish strain

cultivated in Indonesia is *Mutiara* catfish. *Mutiara* catfish itself has several advantages, namely, it has a growth percentage of 10-40% higher than other catfish seeds, has a relatively short maintenance time, a relatively low feed conversion ratio, and a relatively high survival rate (Buwono *et al.*, 2019).

One of the factors that greatly affect the growth of catfish in cultivation is the management of feeding during cultivation. Protein is an important component in the composition of fish feed, this is because protein plays a role in the growth process of body tissues or organs and is actively involved in the body's metabolic processes. The fish feed manufacturing industry takes the protein from animal and vegetable sources. One of the obstacles in feed production is that there is always a fluctuating price increase and scarcity of materials such as fish meal which is used as a source of feed protein (Beski *et al.*, 2015). The increase in the price of feed ingredients, the scarcity of various sources of feed, environmental pressures, and the increasing human population have also caused the demand for animal feed to increase, so that the price of animal protein, especially fish meal, is getting more expensive (Wardhana, 2016). As a result, fish cultivators get the fish meal of poor quality under standard with relatively expensive feed prices (Rambet *et al.*, 2016).

An alternative source of feed is needed to reduce constraints in animal feed production. Maggot (Black soldier fly larvae) is an insect that can be used as an alternative source of feed because it contains several nutrients that fish need, such as relatively high protein content. Maggot larvae have a protein content of around 40-50%. With a relatively high source of nutrients, maggots can stimulate growth and organ formation, such as increasing weight so that it can increase the productivity of fish farming (Wardhana, 2016). The nutritional content of maggots can improve the growth performance of salmon (Belghit *et al.*, 2019). Maggot can also improve

growth performance, body composition, tissue fatty acid composition, and lipid deposition in juvenile Jian carp (Li *et al.*, 2016). Other research has also shown that substituting fishmeal with maggot in the diets can affect growth, nutrient utilization, haemato-physiological response, and oxidative stress biomarkers of African catfish (Fawole *et al.*, 2019).

Fish growth is influenced by the quality and quantity of feed nutrients and the ability of fish to digest food through the digestive system (Yanuar, 2017). The intestine is one of the digestive organs that play a role in the absorption of nutrients in feed. The absorption of nutrients is carried out by the villi on the tunica mucosa which is on the surface of the intestines. Between the villi, there is a small estuary called kripte with the function of forming antibodies or the body's defense system and regenerating damaged villi (Ishan *et al.*, 2018).

Good absorption of feed nutrients can increase growth and muscle mass in fish. The increase in muscle mass can be observed through structural changes in the area of muscle fibers (myofibers). Broad and large muscle fibers can increase fish weight, so that fish growth and productivity are much better. There is not much information about the role of maggot which is used as an alternative source of feed in optimizing the growth and structure of the intestine organs and muscles of the *Mutiara* catfish. This study aims to determine the effect of providing a combination of maggot with commercial pellets on the growth, the structure of the intestine organs, and skeletal muscles of *Mutiara* catfish.

## METHODOLOGY

### Place and Time

The research was conducted from October 20, 2019 to October 20, 2020 at the Laboratory of Animal Structure and Physiology, Universitas Ahmad Dahlan. *Mutiara* catfish taken from the Unit Kerja Budidaya Air Tawar (UKBAT) Cangkringan, Yogyakarta, Indonesia.

## Research Materials

The materials used in this study were maggot larvae, feed commercial HI PROVIT 781, *Mutiara* catfish ( $\pm$  9.88 cm in length and  $\pm$  8.08 g in weight), graded alcohol, xylol, liquid paraffin, Hematoxylin-Eosin (HE) dye, ice water, 0.9% NaCl, Neutral Buffer Formalin 10%. The tools used in this study are digital scales, rulers, containers, microscopes (Olympus CX23), dissection set, and Optilab.

## Research Design

The study used a completely randomized design (CRD) consisting of 4 groups, namely 0% maggot + 100% commercial feed (Control), 25% maggot + 75% commercial feed (P1), 50% maggot + 50% commercial feed (P2), 75% maggot + 25% commercial feed (P3). *Mutiara* catfish seeds were stocked in each treatment with a stocking density of 6 fish/container with 6 replications (24 container).

## Work Procedure

### Acclimatization, Maintenance, and Feeding

Maggots are dried in sunlight until dry, then blended to get maggot flour. Maggot flour is used as a mixture with commercial feed from the HI PROVIT 781 brand with a concentration of 0%, 25%, 50%, and 75% maggot. The commercial feed is mixed with maggot flour until it is evenly distributed, then it is rounded out by adjusting the size of the fish. The four types of feed were then tested proximate to determine the nutritional content of the feed. *Mutiara* catfish were given into a rearing container with a diameter of 34 cm with a water level of 14.5 cm and acclimatized for 7 days. Feeding is carried out 3 times a day, starting at 09.00, 15.00, and 21.00 WIB for 21 days. The amount of feed mixture given to fish is 5% of the average fish weight.

## Absolute Weight Gain and Length Increment of *Mutiara* Catfish

Every week, the weight and length of catfish were measured in each treatment. Then the absolute weight calculation is measured with the following formula (Apriliana *et al.*, 2017):

$$\Delta W = W_t - W_0$$

Where:

$\Delta W$  = absolute weight gain (g)

$W_t$  = final average fish weight (g)

$W_0$  = initial average fish weight (g)

The calculation of the absolute length of the fish uses the following formula (Apriliana *et al.*, 2017):

$$\Delta L = L_t - L_0$$

Where:

$\Delta L$  = absolute length increment (cm)

$L_t$  = final average fish length (cm)

$L_0$  = initial average fish length (cm)

## Euthanasia and Organ Preparation

On the 22<sup>nd</sup> day, *Mutiara* catfish were fasted for 12 hours, then dissected using a dissection set. Subsequently, five fish per group are to be sacrificed by anesthesia (using ice), then dissected and taken organs consisting of intestines and muscles. Measurements of organ weight and length were performed to calculate the organ/total weight ratio.

## Histological Preparation

Intestine and skeletal muscles were cut to a length of 2 cm then washed using NaCl 0.9%. Intestine and skeletal muscles were fixed using Buffer Neutral Formalin 10% solution for 24 hours. Preparations were made using the paraffin method with hematoxylin-eosin staining (Bancroft *et al.*, 2012).

## Histological Structure of Intestine

The parameters of the histological structure of the intestine consist of measuring the height, width, and area of the villi area, villi height, basal width, and apical width calculated under a microscope at a 100x magnification with five fields of view for each preparation. According to Setiawan *et al.* (2018), the

surface area of the villi ( $\mu\text{m}^2$ ) is calculated using the formula:

$$\text{villi area} = \frac{\text{villi basal wide} + \text{villi apical wide}}{\text{villi apical wide} \times \text{villi height}}$$

The depth of the villi crypt is calculated at the base towards the villi surface. The depth of villi crypt was observed in five different fields of view for each preparation. After that, the comparison between the villi length and the villi cryptic depth is calculated using the ratio formula (Fard *et al.*, 2014; Setiawan *et al.*, 2018):

$$\text{villi/crypta} = \frac{\text{average villi height}(\mu\text{m})}{\text{average villi depth}(\mu\text{m})}$$

### Histological Structure of Skeletal Muscle

Observation of skeletal muscle was carried out under a microscope at 100x with 5 fields of view for each preparation and images of the preparations were taken using optilab. The histological structure of the measured skeletal muscles includes the diameter and area of the myofiber.

### Data Analysis

Data were analyzed quantitatively by testing homogeneity and normality. Followed by the one-way ANOVA test then followed by the post hoc Duncan test with a confidence level of 95%.

## RESULTS AND DISCUSSION

### Proximate Test

The proximate test results show that there are differences in the protein content of each maggot feed. Maggot feed content (Table 1) with the highest protein content was found in the 50% and 75% treatment, while the lowest protein content was found in the 0% treatment. All have a protein content above 30% which indicates that the protein content has met the standard needs of fish. The proximate test results (Table 1) also show that the highest fat content is in maggot 75% with a total fat content of 13.72%. Maggot has a high protein content with several variations of amino acids. The amino acid content found in maggot includes tyrosine (7.7g), arginine (5.5 g), histidine (3.1 g), threonine (3.8 g), valine (8.1 g), glycine (0.3 g), alanine (25.68 g), and lysine (6.5 g) on 100 g protein (Khan *et al.*, 2016).

Table 1. Proximate test result on combined maggot with commercial feed.

Treatment	Water (%)	Ash (%)	Protein (%)	Fat (%)	Crude fiber (%)	Carbohydrate (%)	Energy (kal/100g)
0%	9.17	8.70	31.31	4.19	4.22	51.55	370.15
25%	8.92	9.37	34.51	6.74	6.94	42.38	371.72
50%	33.21	12.34	38.91	9.40	13.75	25.55	349.74
75%	11.96	11.01	38.80	13.72	14.23	22.19	375.46

### Fish Growth

The results of observing the growth of *Mutiara* catfish show that maggot feed has no significant effect on body length (Table 2). The growth of catfish body length from day 0 to day 21 and absolute length did not show any significant difference in all treatments ( $P > 0.05$ ). It is

suspected that feeding maggots to *Mutiara* catfish for 21 days has not shown not show the optimum length growth. On the other hand, maggot feed had a significant effect on daily weight on day 21 and the absolute weight of catfish ( $P < 0.05$ ) (Table 2). It is suspected that the nutrition in maggots affects growth by adding weight to the *Mutiara* Catfish.

Table 2. Growth data of *Mutiara* catfish after feeding the maggot combination commercial feed for 21 days.

Variable	Days	Treatment			
		0%	25%	50%	75%
Body Length (cm)	0	9.88 ± 0.31 <sup>a</sup>	9.87 ± 0.22 <sup>a</sup>	9.84 ± 0.35 <sup>a</sup>	9.93 ± 0.15 <sup>a</sup>
	7	11.69 ± 0.55 <sup>a</sup>	11.36 ± 0.50 <sup>a</sup>	11.90 ± 0.80 <sup>a</sup>	12.13 ± 0.96 <sup>a</sup>
	14	13.41 ± 0.81 <sup>a</sup>	13.16 ± 0.69 <sup>a</sup>	13.50 ± 0.96 <sup>a</sup>	14.26 ± 1.53 <sup>a</sup>
	21	14.99 ± 1.21 <sup>a</sup>	15.02 ± 1.11 <sup>a</sup>	15.43 ± 1.07 <sup>a</sup>	15.35 ± 1.65 <sup>a</sup>
Absolute Length (cm)	-	5.10 ± 1.06 <sup>a</sup>	5.18 ± 1.07 <sup>a</sup>	5.58 ± 0.97 <sup>a</sup>	5.47 ± 1.63 <sup>a</sup>
Body Weight (g)	0	8 ± 0.10 <sup>a</sup>	8.06 ± 0.17 <sup>a</sup>	8.12 ± 0.14 <sup>a</sup>	8.07 ± 0.11 <sup>a</sup>
	7	13.12 ± 2.06 <sup>a</sup>	12.14 ± 1.08 <sup>a</sup>	12.60 ± 2.21 <sup>a</sup>	15.78 ± 5.60 <sup>a</sup>
	14	18.27 ± 4.39 <sup>a</sup>	18.46 ± 2.53 <sup>a</sup>	19.38 ± 4.62 <sup>a</sup>	24.28 ± 8.48 <sup>a</sup>
	21	25.68 ± 7.26 <sup>a</sup>	27.31 ± 5.40 <sup>a</sup>	30.36 ± 6.18 <sup>ab</sup>	36.33 ± 6.17 <sup>b</sup>
Absolute Weight (g)	-	27.67 ± 7.16 <sup>a</sup>	19.22 ± 5.27 <sup>a</sup>	22.25 ± 6.23 <sup>ab</sup>	28.25 ± 6.16 <sup>b</sup>

Notes: <sup>a-b</sup> Different notations of numbers followed by different letters on the same line indicate a significant difference. Mean ± SD.

The amino acids glycine and proline in maggots play an important role in the formation and growth of collagen connective tissue and the growth of fish (Gam *et al.*, 2005). Research shows that maggot feed is thought to contain protein which plays a role in helping the process of adding weight to *Mutiara* catfish. Leucine is an essential amino acid that plays an important role in the growth of fish muscles. leucine plays a role in maintaining a balance in protein synthesis with protein overhaul through activation of the Mechanistic Target of Rapamycin (mTOR) pathway. The mTOR pathway plays a role in activating protein synthesis in muscles which leads to an increase in fish body weight. in addition, leucine also acts as an attractant for fish thereby increasing fish appetite (Walrand, 2019). It is suspected that maggot contains leucine which plays a role in increasing the weight of the *Mutiara* Catfish. The maggot feed (75%) has the highest protein content, so it is thought to have a relatively

good growth effect compared to other treatments.

### Structure of Intestine

Observation of intestine organs showed that 75% concentration of maggot feed had significant differences in intestine length and weight as well as total weight/weight ratio compared to other treatments ( $P < 0.05$ ) (Table 3). In the intestine histology observation (Figure 1), it can be seen that 75% of maggot feed has the highest villi compared to other treatments. The depth of kripte in maggot feed is 75% higher than the concentration of 50%, 25%, and control. The villi / kripte ratio and the area of villi also showed that 75% maggot feed had the highest yield compared to other treatments (Table 3). The results of statistical analysis showed that a concentration of 75% maggot feed had a significant difference in villi height, crypt depth, villi/crypto ratio, and villi area compared to other treatments ( $P < 0.05$ ).

Table 3. The structure of *Mutiara* catfish intestine after feeding the maggot combination commercial feed for 21 days.

Variable	Treatment			
	0%	25%	50%	75%
Intestine length (cm)	7.38 ± 0.25 <sup>a</sup>	8.14 ± 0.23 <sup>b</sup>	8.48 ± 0.62 <sup>b</sup>	9.88 ± 0.58 <sup>c</sup>
Intestine weight (g)	0.36 ± 0.03 <sup>a</sup>	0.37 ± 0.02 <sup>a</sup>	0.41 ± 0.03 <sup>a</sup>	0.72 ± 0.46 <sup>b</sup>
intestine weight/body weight ratio	0.014 ± 0.0011 <sup>a</sup>	0.013 ± 0.001 <sup>a</sup>	0.013 ± 0.0008 <sup>a</sup>	0.019 ± 0.0015 <sup>b</sup>
Villi length (µm)	288.84±19.55 <sup>a</sup>	347.28±20.70 <sup>b</sup>	357.75±45.07 <sup>b</sup>	500±23.96 <sup>c</sup>
Crypt depth (µm)	51.11±2.22 <sup>a</sup>	55.58±4.16 <sup>b</sup>	56.75±3.95 <sup>b</sup>	65.95±2.13 <sup>c</sup>
Villi/crypt ratio (µm)	5.70±0.45 <sup>a</sup>	6.32±0.49 <sup>a</sup>	6.36±0.57 <sup>a</sup>	7.62±0.56 <sup>b</sup>
Villi area (µm <sup>2</sup> )	713.72±5.64 <sup>a</sup>	819.18±116.09 <sup>a</sup>	867.55±221.67 <sup>a</sup>	1227±190.24 <sup>b</sup>

Notes: a-c Different notations of numbers followed by different letters on the same line indicate a significant difference. Mean ± SD.

The intestine length in 75% maggot feed had a significant result ( $P < 0.05$ ) compared to other treatments (Table 3). The longer the intestine makes the absorption of nutrients in the feed more optimal because the area of villi also increases the optimization of nutrient absorption. The results of intestine observations in histological preparation (Figure 1) show the initial site of the digestion process and nutrient absorption in feed. The proximal part of the intestine has more villi and plays a role in helping the absorption of nutrients (Hernández *et al.*, 2009).

The protein content in maggot feed is thought to also increase the activity of the protease enzyme in the *Mutiara* catfish intestine, with the function of breaking down protein compounds in feed into amino acids. Amino acids are then absorbed by the villi and enter the blood vessels, then and are used for components making up organs and fish growth. It is suspected that 75% maggot feed affects the increase in the length of the proximal intestine tract (Table 3) compared to other treatments.

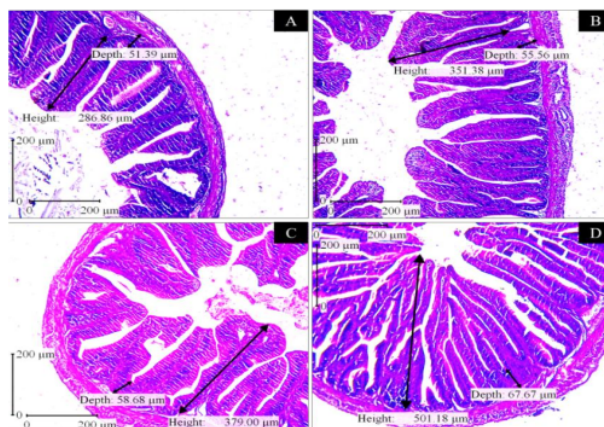


Figure 1. The structure of *Mutiara* catfish intestine after feeding the maggot combination commercial feed for 21 days. Notes: A. 0 % maggot feed, B. 25% maggot feed C. 50% maggot feed, D. 75% maggot feed, Height: shows vili length, Depth: shows crypte depth. Villi at the maggot feed treatment are 75% higher than other treatments. Hematoxylin-eosin staining. Scale Bar 200µm.

The amino acids in maggots can maintain the structure of the intestines if there is tissue damage, thus maintaining the length of the villi and protecting the crypts to keep them intact. When the morphological structure of the intestines is maintained, the absorption of nutrients can also take place optimally (Beski *et al.*, 2015). Nutrients in maggot feed such as histidine can maintain the intestine structure so that the intestine weight does not decrease because the intestine lining remains intact and is not damaged, and the process of absorption of nutrients runs optimally.

The longer villi structure in the intestines can increase the surface area for absorption of nutrients and reduce the speed of the flow of food so that ideal absorption can occur (Ikpegbu *et al.*, 2014). Kripte repaired the mucosal layer when the villi were damaged due to toxins produced by pathogens (Rajput *et al.*, 2013). The depth of crypt in 75% maggot feed had significant results ( $P < 0.05$ ) compared to other treatments (Table 3). According to Jia *et al.* (2006), the content of glycine, cysteine, and serine functions

to protect cells from damage and improve the structure of the intestine tissue. It is suspected that the amino acid content can help speed the repair of villi tissue and protect the intestine structure of *Mutiara* catfish.

### Skeletal Muscle

Increased performance of skeletal muscles such as increased muscle mass and diameter and area of muscle fibers (myofibers) have a particular role in the process of growing fish weight. There is an increase in muscle weight, diameter, and area of myofibers in maggot feeding. The results (Table 4) show that there is a significant difference ( $P < 0.05$ ) in muscle weight in the 75% maggot feed treatment compared to other treatments. In the diameter and area of myofiber, it shows that in 25% maggot feed there is a significant difference with a 0% concentration, and it increases at a dose of 75%. Changes in diameter and area occur as a result of the hypertrophy process, namely the increase in cell size (Johnstone, 2001; Saragih *et al.*, 2017).

Table 4. The Structure of *Mutiara* catfish skeletal muscle after feeding the maggot combination commercial feed for 21 days.

Variable	Treatment			
	0%	25%	50%	75%
Muscle Weight (g)	11.57 ± 0.73 <sup>a</sup>	12.26 ± 0.89 <sup>a</sup>	13.01 ± 0.87 <sup>a</sup>	21.65 ± 1.84 <sup>b</sup>
Myofiber Diameter (µm)	16.27 ± 0.36 <sup>a</sup>	21.30 ± 0.26 <sup>b</sup>	26.56 ± 0.26 <sup>c</sup>	29.77 ± 0.22 <sup>d</sup>
Myofiber (µm <sup>2</sup> )	209.93 ± 10.59 <sup>a</sup>	325.24 ± 13.73 <sup>b</sup>	531.23 ± 8.35 <sup>c</sup>	617.36 ± 4.72 <sup>d</sup>

Notes: <sup>a-c</sup> Different notations of numbers followed by different letters on the same line indicate a significant difference. Mean ± SD.



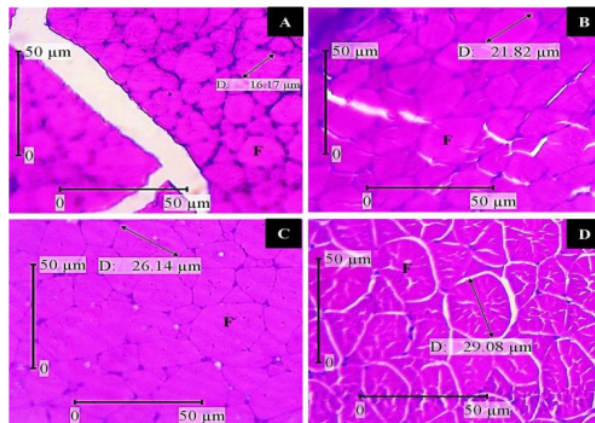


Figure 2. The structure of *Mutiara* catfish skeletal muscle after feeding the maggot combination commercial feed for 21 days. Notes: A. 0% maggot feed, B. 25% maggot feed, C. 50% maggot feed, D. 75% maggot feed, F: myofiber, D: Myofiber diameter. Myofiber at 75% maggot feed bigger than 0% maggot feed. Hematoxylin-eosin staining. Scale bar 50μm.

Some of the nutritional content in maggot feed can increase the body mass of *Mutiara* Catfish, including increasing fish muscle mass. According to Warisan *et al.* (2018) that the lysine contained in the feed is an essential amino acid that functions to activate protein synthesis in muscles, thereby increasing the bodyweight of *Mutiara* catfish. The maggot contains taurine compounds which play a role in increasing fish muscle weight. Wiriduge *et al.* (2020) proved that taurine compounds can increase the hydroxyproline and collagen content in fish muscles. Research results by Wei *et al.* (2016) and Cheng *et al.* (2014) also showed that hydroxyproline and collagen played a role in improving the quality of fish muscles and triggering an increase in fish muscle weight. It is thought that feeding a combination of maggot and commercial pellets containing essential amino acids plays a role in protein synthesis in muscles which leads to muscle hypertrophy (Walrand, 2019).

Fish muscle hypertrophy occurs when the addition of size of the muscle fiber in the fish. The administration of commercial maggots and pellets with a concentration of 25% to 75% has a larger diameter and fiber area than the

administration of maggots and commercial pellets with a concentration of 0% (Figure 2). Fish food that contains protein provides several amino acids such as leucine which can play a role in the protein synthesis process in fish muscles (Walrand, 2019). Zhao *et al.* (2020) proved that the addition of the amino acid leucine significantly increased the expression of the Insulin Growth Factor (IGF-I) and Insulin Growth Factor Receptors (IGF-IR). IGF-I and IGF-IR play a role in stimulating the process of proliferation and differentiation of myoblast cells to initiate growth in fish muscles (Azizi *et al.*, 2016). IGF-I acts as the main promoter in fish muscle growth. IGF-I will attach to a receptor, namely IGF-IR which will activate the signaling pathway Target of Rapamycin (TOR).

The TOR signaling pathway will also phosphorylate, namely eukaryotic translation initiation factor 4E - binding protein 1 (4E-BP1) resulting in eukaryotic translation initiation factor 4E (eIF4E). eIF4E plays a role in starting the translation and elongation process, causing protein synthesis in the muscles which lead to fish muscle hypertrophy (Fuentes *et al.*, 2013). It is suspected that maggot feed contains leucine which plays

a role in increasing the production of IGF-I and IGF-IR which play a role in activating the TOR signaling line. The signaling can trigger and increase muscle protein synthesis, increasing the diameter and area of myofiber *Mutiara* catfish. The increase in myofiber triggers an increase in skeletal muscle weight of *Mutiara* catfish.

## CONCLUSION

The conclusion shows that maggot can be used as an alternative source of protein in the feed because the combination maggot 75% with commercial feed can increase the absolute weight, the structure of intestine and skeletal muscles *Mutiara* catfish for 21 days.

## ACKNOWLEDGMENT

The author acknowledges financial support from Lembaga Penelitian dan Pengabdian Masyarakat (LPPM) UAD 2020. The author would like to thank all parties who have supported the accomplishment of this research.

## REFERENCES

- Apriliansa, R., Basuki, F. and Nugroho, R.A., 2017. Pengaruh pemberian recombinant growth hormone (rGH) dengan dosis berbeda pada pakan buatan terhadap pertumbuhan dan kelulushidupan benih ikan tawes (*Puntius* sp.). *Jurnal Sains Akuakultur Tropis*, 2(1), pp.49-58. <https://doi.org/10.14710/sat.v2i1.2561>
- Azizi, S., Nematollahi, M.A., Amiri, B.M., Velez, E.J., Lutfi, E., Navarro, I., Capilla, E. and Gutiérrez, J., 2016. Lysine and leucine deficiencies affect myocytes development and IGF signaling in gilthead sea bream (*Sparus aurata*). *PLoS ONE*, 11(1), e0147618. <https://doi.org/10.1371/journal.pone.0147618>
- Bancroft, J., Layton, C. and Suvarna, K., 2012. Bancroft's theory and practice of histological techniques. 7<sup>ed</sup>. Sheffield UK, Churchill Livingstone. pp.69-185.
- Belghit, I., Liland, N.S., Gjesdal, P., Biancarosa, I., Menchetti, E., Li, Y., Waagbø, R., Kroghal, Å. and Lock, E.J., 2019. Black soldier fly larvae meal can replace fish meal in diets of sea-water phase Atlantic salmon (*Salmo salar*). *Aquaculture*, 503, pp.609-619. <https://doi.org/10.1016/j.aquaculture.2018.12.032>
- Beski, S.S.M., Swick, R.A. and Iji, P.A., 2015. Specialized protein products in broiler chicken nutrition: A review. *Animal Nutrition*, 1(2), pp.47-53. <https://doi.org/10.1016/j.aninu.2015.05.005>
- Buwono, I., Junianto, Iskandar and Alimuddin, 2019. Growth and expression level of growth hormone in transgenic mutiara catfish second generation. *Journal of Biotech Research*, 10, pp.102-109. <http://www.btsjournals.com/assets/2019v10p102-109.pdf>
- Cheng, J.H., Sun, D.W., Han, Z. and Zeng, X.A., 2014. Texture and structure measurement and analyses for evaluation of fish and fillet freshness quality : A review. *Comprehensive Reviews in Food Science and Food Safety*, 13(1), pp.52-61. <https://doi.org/10.1111/1541-4337.12043>
- Fard, S.H., Toghyani, M. and Tabeidian, S.A., 2014. Effect of oyster mushroom wastes on performance immune responses and intestine morphology of broiler chickens. *International Journal of Recycling of Organic Waste in Agriculture*, 3, pp.141-146. <https://doi.org/10.1007/s40093-014-0076-9>
- Fawole, F.J., Adeoye, A.A., Tihamiyu, L.O., Ajala, K.I., Obadara, S.O. and Ganiyu, I.O., 2019. Substituting fishmeal with *Hermetia illucens* in the diets of African catfish (*Clarias gariepinus*): Effects on growth, nutrient utilization, haemato-physiological response, and oxidative stress biomarker. *Aquaculture*, 518, 734849. <https://doi.org/10.1016/j.aquaculture.2019.07.049>

- oi.org/10.1016/j.aquaculture.2019.734849
- Fuentes, E.N., Valdés, J.A., Molina, A. and Björnsson, B.T., 2013. Regulation of skeletal muscle growth in fish by the growth hormone–insulin-like growth factor system. *General and Comparative Endocrinology*, 192, pp.1-13. <https://doi.org/10.1016/j.ygcen.2013.06.009>
- Gam, L.H., Leow, C.Y. and Baie, S., 2005. Amino acid composition of snakehead fish (*Channa striatus*) of various sizes obtained at different times of the year. *Malaysia Journal of Pharmaceutical Sciences*, 3(2), pp.19-30. <http://web.usm.my/mjps/volo3no2.html>
- Hernández, D.R., Gianeselli, M.P. and Domitrovic, H.A., 2009. Morphology histology and histochemistry of the digestive system of South American Catfish (*Rhamdia quelen*). *International Journal of Morphology*, 27(1), pp.105-111. <http://dx.doi.org/10.4067/S0717-95022009000100019>
- Ikpegbu, E., Nlebedum, U.C. and Ibe, C.S., 2014. The histology and mucin histochemistry of the farmed juvenile African Catfish digestive tract (*Clarias gariepinus* B). *Studia Universitatis "Vasile Goldis", Seria Stiintele Vietii*, 24(1), pp.125-131. <http://www.studiauniversitatis.ro/2014/11/17/the-histology-and-mucin-histochemistry-of-the-farmed-juvenile-african-catfish-digestive-tract-clarias-gariepinus-b/>
- Jia, C.J., Dai, C.L., Zhang, X., Cui, K., Xu, F. and Xu, Y.Q., 2006. Alanyl-glutamine dipeptide inhibits hepatic ischemia-reperfusion injury in rats. *World Journal of Gastroenterology*, 12(9), pp.1373-1378. <https://doi.org/10.3748/wjg.v12.i9.1373>
- Johnstone, I.A.N., 2001. *Muscle and development*. Academic Press, San Diego, California, pp.104-105.
- Ishan, Z.K., Ilmiawan, M.I., Zakiah, M. and Nawangsari, 2018. Gambaran histopatologi dan kemampuan regenerasi duodenum tikus putih (*Rattus norvegicus*) jantan dewasa setelah penghentian pajanan monosodium glutamat. *Jurnal Mahasiswa PSPD FK Universitas Tanjungpura*, 4(4), pp.1193-1202. <https://jurnal.untan.ac.id/index.php/jfk/article/view/32880>
- Khan, S., Khan, R.U., Sultan, A., Khan, M., Hayat, S.U. and Shahid, M.S., 2016. Evaluating the suitability of maggot meal as a partial substitute of soya bean on the productive traits, digestibility indices and organoleptic properties of broiler meat. *Journal of Animal Physiology and Animal Nutrition*, 100(4), pp.649-656. <https://doi.org/10.1111/jpn.12419>
- Li, S., Ji, H., Zhang, B., Tian, J., Zhou, J. and Yu, H., 2016. Influence of black soldier fly (*Hermetia illucens*) larvae on growth performance, body composition, tissue fatty acid composition and lipid deposition in juvenile Jian carp (*Cyprinus carpio* var. Jian). *Aquaculture*, 465, pp.43-52. <https://doi.org/10.1016/j.aquaculture.2016.08.020>
- Rajput, N., Muhammad, N., Yan, R., Zhong, X. and Wang, T., 2013. Effect of dietary supplementation of curcumin on growth performance intestine morphology and nutrients utilization of broiler chicks. *The Journal of Poultry Science*, 50(1), pp.44-52. <https://doi.org/10.2141/jpsa.0120065>
- Rambet, V., Umboh, J.F., Tulung, Y.L.R. and Kowel, Y.H.S., 2016. Kecernaan protein dan energi ransum broiler yang menggunakan tepung maggot (*Hermetia illucens*) sebagai pengganti tepung ikan. *Zootec*, 36(1), pp.13-22. <https://doi.org/10.35792/zot.36.1.2016.9314>
- Saragih, H.T.S.S.G., Alawi, M.F., Rafieiy, M., Lesmana, I. and Sujadmiko, H., 2017. Supplementation of ethanolic extract of marchantia in pre-starter diet improves the growth of duodenu and pectoralis thoracicus.

- Jurnal Veteriner*, 18(4), pp.617-623.  
<https://doi.org/10.19087/jveteriner.2017.18.4.617>
- Setiawan, H., Jingga, M.E. and Saragih, H.T., 2018. The effect of cashew leaf extract on small intestine morphology and growth performance of *Jawa Super* Chicken. *Veterinary World*, 11(8), pp.1047-1054. <https://doi.org/10.14202/vetworld.2018.1047-1054>
- Walrand, S., 2019. *Nutrition and skeletal muscle*. Academic Press, London, pp.139-150, 263-271.
- Wardhana, A.H., 2016. Black soldier fly (*Hermetia illucens*) as an Alternative Protein Source for Animal Feed. *Wartazoa*, 26(2), pp.69-78. <https://dx.doi.org/10.14334/wartazoa.v26i2.1327>
- Warisan, Sasanti, A.D. and Yulisman, 2018. Kandungan lisin dan pertumbuhan ikan gabus (*Channa striata*) yang diberi pakan berbeda. *Prosiding Seminar Nasional Lahan Suboptimal*. Unsri Press, pp.384-393. <http://www.conference.unsri.ac.id/index.php/lahansuboptimal/article/view/1269>
- Wei, Z., Ma, J., Pan, X., Mu, H., Li, J., Shentu, J., Zhang, W. and Mai, K., 2016. Dietary hydroxyproline improves the growth and muscle quality of large yellow croaker *Larimichthys crocea*. *Aquaculture*, 464, pp.497-504. <https://doi.org/10.1016/j.aquaculture.2016.07.015>
- Wiriduge, W., Sampath, H.A., Zhang, Y., Liu, J., Yang, M., Zhang, W. and Mai, K., 2020. Dietary taurine improves muscle growth and texture characteristics in juvenile turbot (*Scophthalmus maximus*). *Aquaculture Reports*, 17, 100305. <https://doi.org/10.1016/j.aqrep.2020.100305>
- Yanuar, V., 2017. Pengaruh pemberian jenis pakan yang berbeda terhadap laju pertumbuhan benih ikan nila (*Oreochromis niloticus*) dan kualitas air di akuarium pemeliharaan. *Ziraa'ah Majalah Ilmiah Pertanian*, 42(2), pp.91-99. <https://doi.org/10.31602/zmip.v42i2.772>
- Zhao, Y., Li, J.Y., Jiang, Q., Zhou, X.Q., Feng, L., Liu, Y., Jiang, W.D., Wu, P., Zhou, J., Zhao, J. and Jiang, J., 2020. Leucine improved growth performance, muscle growth, and muscle protein deposition through AKT/TOR and AKT/FOXO3a signaling pathways in hybrid catfish *Pelteobagrus vachelli* X *Leiocassis longirostris*. *Cells*, 9(2), p.327. <https://doi.org/10.3390/cells9020327>

# HASIL CEK\_Jurnal Haris 2-dikonversi

## ORIGINALITY REPORT

7%

SIMILARITY INDEX

6%

INTERNET SOURCES

7%

PUBLICATIONS

1%

STUDENT PAPERS

## PRIMARY SOURCES

1	<a href="http://journal.ugm.ac.id">journal.ugm.ac.id</a> Internet Source	1%
2	<a href="http://puipk.poltekkesbengkulu.ac.id">puipk.poltekkesbengkulu.ac.id</a> Internet Source	1%
3	Nurul Khairani, Santoso Ujang Effendi. "Family characteristics as risk factors of stunting among children age 12-59 month", Jurnal Aisyah : Jurnal Ilmu Kesehatan, 2019 Publication	1%
4	<a href="http://jppipa.unram.ac.id">jppipa.unram.ac.id</a> Internet Source	1%
5	<a href="http://doaj.org">doaj.org</a> Internet Source	1%
6	<a href="http://jpi.faterna.unand.ac.id">jpi.faterna.unand.ac.id</a> Internet Source	1%
7	Hang Yang, Mohammad Mizanur Rahman, Xiaoqin Li, S.M. Sharifuzzaman, Xiangjun Leng. "Dietary leucine requirement of juvenile largemouth bass ( <i>Micropterus salmoides</i> ) based on growth, nutrient utilization and	1%

# growth-related gene analyses", Aquaculture, 2022

Publication

---

8

Khursheed Ahmad Shiekh, Mooksupang Liangpanth, Siriporn Luesuwan, Rinlane Kraisitthisirintr et al. "Preparation and Characterization of Bioactive Chitosan Film Loaded with Cashew (*Anacardium occidentale*) Leaf Extract", *Polymers*, 2022

Publication

---

1 %

9

[dergipark.org.tr](http://dergipark.org.tr)

Internet Source

---

1 %

---

Exclude quotes      On

Exclude matches      < 1%

Exclude bibliography      On