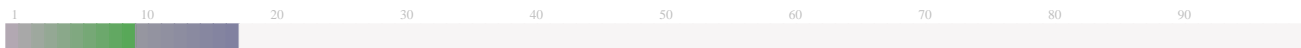


### Submission Information

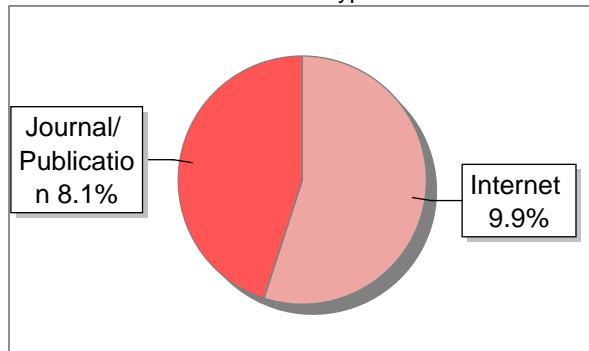
Author Name	Tendik
Title	Artikel
Paper/Submission ID	1949535
Submitted by	dian.yunihassti@staff.uad.ac.id
Submission Date	2024-06-05 11:25:09
Total Pages, Total Words	12, 4306
Document type	Article

### Result Information

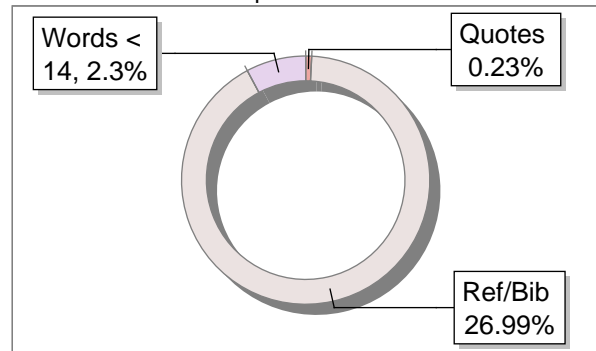
Similarity **18 %**



Sources Type



Report Content



### Exclude Information

Quotes	Not Excluded
References/Bibliography	Not Excluded
Source: Excluded < 14 Words	Not Excluded
Excluded Source	<b>0 %</b>
Excluded Phrases	Not Excluded

### Database Selection

Language	Non-English
Student Papers	Yes
Journals & publishers	Yes
Internet or Web	Yes
Institution Repository	Yes

A Unique QR Code use to View/Download/Share Pdf File



## DrillBit Similarity Report

**18**

SIMILARITY %

**34**

MATCHED SOURCES

**B**

GRADE

**A-Satisfactory (0-10%)****B-Upgrade (11-40%)****C-Poor (41-60%)****D-Unacceptable (61-100%)**

LOCATION	MATCHED DOMAIN	%	SOURCE TYPE
1	<a href="http://eurekaselect.com">eurekaselect.com</a>	2	Internet Data
2	<a href="http://tdtmvjournal.biomedcentral.com">tdtmvjournal.biomedcentral.com</a>	2	Internet Data
3	<a href="http://uir.unisa.ac.za">uir.unisa.ac.za</a>	1	Publication
4	<a href="http://journal.umy.ac.id">journal.umy.ac.id</a>	1	Publication
5	<a href="http://core.ac.uk">core.ac.uk</a>	1	Publication
6	Systemic alterations induced by phospholipase A, by Costa, Kellen Crist-2018	1	Publication
7	<a href="http://www.ijccm.org">www.ijccm.org</a>	1	Publication
8	<a href="http://bmcpublichealth.biomedcentral.com">bmcpublichealth.biomedcentral.com</a>	1	Publication
9	Proteomic Analysis of Novel Components of Nemopilema nomurai Jellyfish Venom De by Choudhary-2019	1	Publication
10	<a href="http://www.dx.doi.org">www.dx.doi.org</a>	1	Publication
11	<a href="http://dovepress.com">dovepress.com</a>	1	Internet Data
12	<a href="http://en.wikipedia.org">en.wikipedia.org</a>	1	Internet Data
13	<a href="http://pubmed.ncbi.nlm.nih.gov">pubmed.ncbi.nlm.nih.gov</a>	1	Internet Data

14	<a href="http://repository.unair.ac.id">repository.unair.ac.id</a>	1	Internet Data
15	<a href="http://www.graphyonline.com">www.graphyonline.com</a>	1	Internet Data
16	<a href="http://biomedgrid.com">biomedgrid.com</a>	<1	Internet Data
17	<a href="http://documentop.com">documentop.com</a>	<1	Internet Data
18	<a href="http://www.scireslit.com">www.scireslit.com</a>	<1	Publication
19	<a href="http://www.dentalperfections.co.uk">www.dentalperfections.co.uk</a>	<1	Internet Data
20	<a href="http://mdpi.com">mdpi.com</a>	<1	Internet Data
21	<a href="http://academicjournals.org">academicjournals.org</a>	<1	Publication
22	<a href="http://s-space.snu.ac.kr">s-space.snu.ac.kr</a>	<1	Internet Data
23	<a href="http://www.frontiersin.org">www.frontiersin.org</a>	<1	Internet Data
24	<a href="http://1library.co">1library.co</a>	<1	Internet Data
25	<a href="http://dovepress.com">dovepress.com</a>	<1	Internet Data
26	<a href="http://repositorio-aberto.up.pt">repositorio-aberto.up.pt</a>	<1	Publication
27	<a href="http://adoc.pub">adoc.pub</a>	<1	Internet Data
28	Blood coagulation, fibrinolysis and platelet function in obese subject by K-1972	<1	Publication
29	Economical and environment-friendly approaches for usage of onion ( <i>Allium cepa</i> L by Sharma-2016	<1	Publication
30	<a href="http://jisprm.org">jisprm.org</a>	<1	Internet Data
31	<a href="http://moam.info">moam.info</a>	<1	Internet Data

<b>32</b>	Nationwide Survey of Pediatric Inpatients With Hand, Foot, and Mouth Disease, He by Takechi-2019	<1	Publication
-----------	--	----	-------------

---

<b>33</b>	<a href="https://repository.uel.ac.uk">repository.uel.ac.uk</a>	<1	Publication
-----------	---	----	-------------

---

<b>34</b>	<a href="http://www.hilarispublisher.com">www.hilarispublisher.com</a>	<1	Internet Data
-----------	--	----	---------------

---



## Article

# Stroke Hemorrhagic after Snakebite: A Scoping Review

<sup>1</sup>Ana Budi Rahayu, <sup>2</sup>Dewi Yuniasih\*, <sup>3</sup>Novi Wijayanti Sukirto.

Email (Corresponding Author): \* [dewi.yuniasih@med.uad.ac.id](mailto:dewi.yuniasih@med.uad.ac.id)

<sup>1</sup>Department of Neurology, Faculty of Medicine, Universitas Ahmad Dahlan, Yogyakarta

<sup>2</sup>Department of Public Health, Faculty of Medicine, Universitas Ahmad Dahlan, Yogyakarta

<sup>3</sup>Department of Internal Medicine, Faculty of Medicine, Universitas Ahmad Dahlan, Yogyakarta

### ARTICLE INFO

**Article history**  
Received 22-04-24  
Revised 25-05-24  
Accepted 25-05-24

**Keywords**  
Bohtropp spp;  
Cerebral complication;  
Hemorrhagic;  
Snakebite;  
Stroke,

### ABSTRACT

Snakebite envenomation is a neglected tropical disease that affects millions of individuals living in underdeveloped countries. Cerebral complications are often found in venomous snake bite victims. Certain snake venoms can interfere with the blood's ability to clot, increasing the risk of bleeding in the brain and potentially causing a stroke. Previous literature review studies have not comprehensively reviewed stroke hemorrhagic after snake bites. Therefore, we are interested in conducting a literature review using the scoping review method on stroke hemorrhagic after snake bites. The samples in this study were published articles from international journals related to cerebral complications after snakebite that met the inclusion and exclusion criteria. The inclusion criteria used in this study were articles derived from the PubMed, ScienceDirect, and Scopus databases, using the keywords "Snakebite" OR "Snake envenoming" AND "Stroke hemorrhagic". Based on the eligibility, Six articles were finally synthesized in the study. All of papers were a case report design. Three cases were from Brazil, three cases from Morocco, Burkina Faso and Togo. The snake that causes hemorrhagic stroke in Brazil is Bothrops spp. however, the type of snake in the instances from Burkina Faso and Morocco is unknown. There were a total of 10 instances reported from 6 journals. One patient from Morocco died, while another patient from Brazil suffered from prolonged hemiplegia. Furthermore, a total of 8 more patients were released from the hospital in an improved condition.

This is an open-access article under the CC-BY-SA license.



## INTRODUCTION

Snakebite is a Neglected Tropical Disease that affects many tropical and subtropical countries<sup>1</sup>. Every year, venomous snake bites kill over 100,000 people around the world. The World Health Organization (WHO) predicts that 5.4 million snakebite incidents will occur annually<sup>2</sup>. Several factors contribute to snakebite deaths, including the victim's condition, first

aid<sup>3</sup>, access to adequate facilities<sup>4</sup>, the availability of antivenom<sup>5</sup>, and the level of venom<sup>6</sup> in the biting snake.

Snake venom contains a complex combination of enzymes, lipids, nucleotides, and carbohydrates<sup>7</sup>. Snake venom has three types of toxins: hemotoxins, neurotoxins, and cytotoxins<sup>7</sup>, all of which induce systemic damage and can lead to brain or cerebral issues. Cerebral complications are often found in venomous snake bite victims. Cerebral complications refer to the potential effects on <sup>17</sup> the brain and central nervous system caused by a venomous snake bite. Venom injected into the body can spread through the bloodstream and affect various organs, including the brain. Three main venoms in snake venom, including hemotoxins, neurotoxins, and cytotoxins, cause cerebral complications<sup>8</sup>.

Some of the pathophysiological mechanisms involved in complications due to snakebites include local toxicity where snake venom can cause tissue damage around the bite area<sup>9</sup>. <sup>19</sup> This can lead to pain, swelling, and infection. Additionally, Systemic toxicity where snake venom can spread through the bloodstream throughout the body, affecting various organs and systems. This can lead to complications such as respiratory distress, blood clotting disorders, kidney damage, or central nervous system damage<sup>9</sup>.

Another effect of snake bites is the neurotoxic effect<sup>9,10</sup> as some types of snake venom contain neurotoxins that can affect the nervous system. <sup>19</sup> This can cause symptoms such as muscle weakness, paralysis, impaired coordination, or seizures<sup>9,11</sup>. Hemotoxic effects occur when snake venom <sup>29</sup> can damage red blood cells or affect the blood's ability to clot. This can lead to anemia, clotting disorders, or internal bleeding<sup>12</sup>. Specific snake venoms can disrupt the blood's clotting mechanism, heightening the likelihood of cerebral hemorrhage and potentially leading to a stroke<sup>13,14</sup>.

Several cerebral complications such as cerebral hemorrhage<sup>15</sup>, ischemic stroke<sup>16</sup>, cerebral infarction<sup>17</sup>, and secondary inflammation often occurs after a venomous snake bite due to hemotoxic enzymes such as snake-venom metalloproteinases (SVMPs), coagulant enzymes, and proteolytic enzyme toxicity. These compounds cause severe irreversible brain edema leading to death<sup>18</sup>. Cerebral complications occur variably depending on the type of snake and the venom involved<sup>16</sup>. This maximizes the determination of appropriate medical measures such as antivenom administration, supportive care, and monitoring to minimize the impact of cerebral complications after snakebite<sup>19</sup>.

Cerebral difficulties following a snake bite arise from the interplay between the venom and the body's physiological functions. When a venomous snake bites, it introduces its venom <sup>5</sup> into the bloodstream of the victim<sup>20</sup>. The venom comprises a range of poisons that can exert systemic effects, including on <sup>17</sup> the brain and central nervous system<sup>21</sup>. The precise pathophysiological pathways may differ <sup>3</sup> depending on the kind of snake and the composition of

its venom. Cerebral difficulties following snakebite often arise due to decreased blood flow caused by the venom's impact on the blood vessels, resulting in vasculitis (inflammation of the blood vessels) or damage to the endothelial cells<sup>8</sup>. This can result in impaired blood flow to the brain, causing ischemia (lack of oxygen) and subsequent cerebral complications<sup>22</sup>. Another mechanism is Coagulopathy where some snake venoms can interfere with the body's normal blood clotting mechanism. This can lead to abnormal bleeding, including within the brain, leading to hemorrhagic complications such as stroke or cerebral hemorrhage<sup>23</sup>.

Some common brain complications that can occur after a snakebite include (World Health Organization, 2016) Cerebral edema, snake venom can cause swelling in the brain, leading to increased pressure and potentially damaging brain tissue. In addition, Encephalopathy refers to generalized dysfunction or damage to the brain, which can result in symptoms such as confusion, altered mental status, or seizures. Encephalopathy is a condition of dysfunction or damage to the brain that can occur after a venomous snake bite. A venomous snakebite can cause the entry of venom into the body, which can then affect various organs including the brain<sup>24</sup>. Encephalopathy<sup>25</sup> after a snakebite may cause symptoms such as confusion, changes in consciousness, or seizures<sup>26</sup>. This is due to the effects of snake venom on the central nervous system, including the brain<sup>26</sup>.

The two most common forms of stroke are hemorrhagic stroke and ischemic stroke<sup>27</sup>. An analysis of 83 case reports on snake envenomation causing cerebrovascular accidents revealed that 77% of the cases resulted in ischemic stroke, 21% had cerebral bleeding, and both stroke and hemorrhage occurred in 2% of the cases. The fatality rate was reported to be 17%<sup>28</sup>. The Viperidae group of snakes have venoms, and haemorrhagins, which are reported to cause endothelial damage and increased vascular permeability, leading to hemorrhagic stroke<sup>9</sup>.

However, previous literature review studies have not comprehensively reviewed stroke hemorrhagic after snake bites. Therefore, the researchers were interested in conducting a literature review using the scoping review method on stroke hemorrhagic after snake bites.

## METHODS

The samples in this study were published articles from international journals related to cerebral complications after snakebite that met the inclusion and exclusion criteria. The inclusion criteria used in this study were articles derived from the PubMed, ScienceDirect, and Scopus databases, using the keywords "Snakebite" [Mesh] OR "Snake envenoming" AND "Stroke hemorrhagic" [Mesh]. Scoping review data collection in the form of articles was obtained based on articles published in the span of 10 years, 2014-2023, fully accessible, English language, and observational studies. To find any more studies, the reference lists of pertinent articles were also

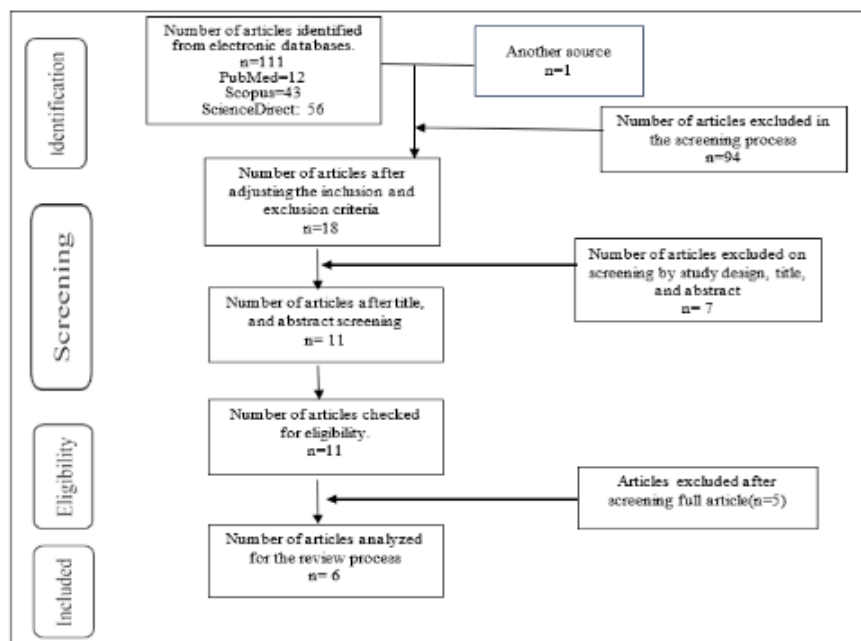
carefully examined. The exclusion criteria in this study are articles that do not match the eligibility criteria and there are duplicates. Eligible articles will be entered into a synthesis table containing the article title, author, country of origin, research design, research objectives, research results, and discussion.

The table discussion is explained in narrative form and grouped according to the theme of the discussion obtained in the research results. It is expected that the results of the study will reveal the characteristics of patients, mechanisms of stroke after snakebite, and the responsible snake of snakebite. The narrative will also illustrate which country has the most information related to stroke after a snakebite and also the research design conducted.

## RESULTS

A total of 111 articles were retrieved from the database, and an additional article was found through a search of relevant references. A total of 94 articles were removed throughout the screening process due to their non-English language or lack of open access availability. After doing a comprehensive evaluation of the study design, title, and abstract, we once again eliminated 7 publications. Upon thoroughly examining the complete content, we analyzed a total of 6 articles for the review process.

Table 1. provides a descriptive presentation of all six articles.





Tabel 2. Extraction Results

No	Title	Year	Country	Studi design	Objective	Cases (n)/Age (year)	Neurological manifestation/ deficits	Finding
1	Hemorrhagic stroke following snake bite in Burkina Faso (West Africa). A case series <sup>27</sup>	2021	Burkina Faso	A case series	The objective of this study was to determine the neurological complications following snakebite	3 cases (16, 30 and 55 years)	ptosis, coma, and motor impairment	The study included three occurrences of hemorrhagic stroke after a snake bite. Four to fifteen days after the snakebite, the strokes happened. Significant side effects included severe anemia in two of the individuals who had blood transfusions as well as localized symptoms. Anti-venom for snakes was used. Upon admission, the most common complaints were fever, consciousness problems, and motor deficits. Throughout their hospital stay, patients got repeated doses of antibiotherapy, antitetanus prophylaxis, and snake anti-venom. Most of the patients had fully healed. LOS 23,16 and 51 days. In all cases, the patient was unaware of the sort of snake.
2	Hemorrhagic Stroke Revealing a Snake Bite: A Case Report <sup>29</sup>	2022	Moroko	A Case Report	To present the patient in his 50s who suffered a snakebite and describe the neurological sequelae	1 case/ 50 years	unconscious	A fifty-year-old patient recounted the neurological aftereffects of a snakebite. The patient was brought unconscious to the emergency room. Intracerebral hematomas and meningeal bleeding were discovered during an emergency brain scan. The results of the biological evaluation showed diffused intravascular coagulation. The patient's clinical course swiftly deteriorated, and within 24 hours of arrival, she passed away.
3	Hemorrhagic stroke in children caused by Bothrops marajoensis envenoming: a case report <sup>30</sup>	2015	Brazil	a case report	This work reports the hemorrhagic stroke in a child,	1 case/	permanent hemiplegia.	A kid suffering a hemorrhagic stroke, which was caused by a delay in seeking medical attention following a snakebite envenomation by Bothrops marajoensis in Anajás city, Marajó Island, Pará, Brazil. The result was a permanent hemiplegia as a consequence of delayed medical treatment following snakebite envenoming by Bothrops marajoensis in Brazil.

4	Cerebrovascular Accidents Related to Snakebites in the Amazon-Two Case Reports <sup>31</sup>	2020	Brazil	Two Case Reports	To describe patients with subarachnoid hemorrhage, hydrocephalus and hemoventricle after a snakebite caused by presumed Bothrops ssp	2 cases/ 65 and 22 yearx	lethargic, sleepy, and had mydriatic but responsive pupils.  Unconscious, GCS 8	A suspected Bothrops ssp. snakebite resulted in subarachnoid hemorrhage, hydrocephalus, and hemoventricle in two patients. Delays in the delivery of AV treatment were present in both cases, which could have played a role in the development of problems like stroke. The first patient was brought to the hospital 16 hours after the snakebite. She experienced a subarachnoid hemorrhage accompanied by hemoventricle and hydrocephalus, known as a hemorrhagic stroke. She was released from the hospital on the seventh day. The time from the accidents to hospital was 16 hours and 3 days. A worse outcome may occur if medical treatment is delayed following snake envenomation.
5	Hemorrhagic stroke secondary to Bothrops spp. venom: A case report <sup>32</sup>	2017	Brazil	a case report	To highlight the importance of prior knowledge of possible complications of Bothrops spp. venom to improve the effectiveness of adequate treatment.	1 case/ 58 years	deterioration of consciousness, speech disturbances and left-sided hemiparesis	The female victim of bothrops spp. snakebite, age 58, is described in this case study. The two days following the snakebite were marked by hemorrhagic stroke and blood dyscrasia. A cautious strategy was implemented along with the administration of anti-Bothrops serum. The patient improved after nine days and made a good recovery in terms of function.
6	Two Cases of Hemorrhagic Stroke Following Snake Bite in Kara Teaching Hospital in a Semi Rural Area in Togo	2018	Togo	Case report	describing two clinical examples of hemorrhagic stroke that were observed at Kara Teaching Hospital after a viperid bite.	2 cases/ 27 and 31 years	hemiparesis and aphasia.	Two cases of late-treated envenomation complicated by hemorrhagic stroke. Two weeks after being bitten by a viperidae, a 27-year-old woman was admitted with right hemiparesis and aphasia. the second patient, a 31-year-old man, showed signs of left hemiparesis twelve days later.. On CT scan, hemorrhagic stroke was seen in both patients.. Both of them benefited from the outcome.

## DISCUSSION

All six research we analyzed employed a case report design. Three instances were recorded concerning Brazil as the nation where the incident occurred, while an additional three publications concentrated on Morocco<sup>29</sup>, Burkina Faso<sup>27</sup>, and Togo<sup>33</sup>.

The study done in Burkina Faso documented three distinct instances. The initial incident included the basal ganglia and impacted the internal capsule and lenticular nuclei. The second instance impacted the frontal and cerebellar regions bilaterally in the brain. The third instance had a bleed in the temporal area<sup>27</sup>. Regarding the snake species responsible for the cases, all reports from Brazil attribute it to *Bothrops* spp., while the specific snake type involved in the instances from Burkina Faso and Morocco remains unidentified.

Three articles<sup>30-32</sup> from Brazil reported patients with *Bothrops* spp bites resulting in hemorrhagic strokes. The presence of metalloproteinases in the venom of *Bothrops* spp. is responsible for the vascular and hemorrhagic consequences. In Brazil, there are an average of 26,000 snakebite episodes each year that require medical attention, and out of these incidents, 0.4% result in fatalities<sup>34</sup>. *Bothrops* spp. are the most commonly reported snakes involved in snakebite incidents in Brazil<sup>31</sup>.

Three instances of hemorrhagic stroke resulting from envenomation in Burkina Faso<sup>27</sup>. All of the cases were of young patients (under 65 years old) who did not have any vascular risk factors. This aligns with other studies which found that only 2% of snakebite victims had a medical history of hypertension or diabetes mellitus<sup>28</sup>.

The combined patient population from these 6 papers amounted to 10 individuals. Among them, one patient from Morocco<sup>29</sup> succumbed to the condition, while another patient from Brazil<sup>30</sup> experienced persistent hemiplegia. Meanwhile, 8 additional patients were discharged from the hospital in a better state of health<sup>27,31,32 33</sup>. This outcome may be because the patients received multiple courses of antibiotic treatment, preventive measures against tetanus, and anti-venom for snake bites<sup>27,31,33</sup>. Additionally, a careful approach was taken while administering anti-*Bothrops* serum<sup>32</sup>.

### Mechanisms of Bleeding

Bleeding occurs due to the antithrombotic properties of many constituents present in the venom, including as metalloproteases, serine proteinases, and phospholipases A<sub>2</sub><sup>35</sup>. These components lead to the usage of platelets, fibrinogen, and other coagulation factors. Coagulopathy-induced systemic bleeding can affect the central nervous system. Cerebrovascular issues occur in around 3% of patients who are bitten by *Bothrops* snakes<sup>36</sup>. Among those

patients, a majority of 63% do not survive, while the remaining individuals experience long-lasting and irreversible damage<sup>36</sup>.

Numerous clinical and biological disorders, such as local and systemic bleeding, incoagulability, thrombotic microangiopathy, and macrothrombosis, are brought on by toxins from *Bothrops* venoms that target hemostasis. Toxins are implicated in the pathophysiology of edema<sup>37</sup> and most sequelae, including hypovolemia<sup>38</sup>, cardiovascular collapse, acute renal injury<sup>39</sup>, myonecrosis, compartmental syndrome<sup>40</sup>, and superinfection, in addition to hemostasis abnormalities. These poisons fall into two categories: non-enzymatic proteins (disintegrins and C-type lectin proteins)<sup>7</sup> and enzymatic proteins (snake venom metalloproteinases, snake venom serine proteases, phospholipases A2 and L-amino acid oxidases). Multifocal toxicity that targets platelets, coagulation factors, and arteries is the cause of bleeding<sup>41</sup>.

Toxins found in *Bothrops* venoms<sup>23</sup> can disrupt hemostasis, leading to various clinical and biological problems such as local and systemic bleeding, incoagulability, thrombotic microangiopathy, and macrothrombosis. Toxins **5** play a role in the development of edema and its associated complications, such as hypovolemia, cardiovascular collapse, acute renal damage, myonecrosis, compartmental syndrome, and superinfection, **as well as** anomalies in hemostasis<sup>42,43</sup>. The poisons **can be classified** into two groups: non-enzymatic proteins (disintegrins and C-type lectin proteins) and enzymatic proteins (snake venom metalloproteinases, snake venom serine proteases, phospholipases A2, and L-amino acid oxidases)<sup>44</sup>. The cause of bleeding is multifocal toxicity that specifically affects platelets, coagulation factors, and arteries<sup>23</sup>.

### Neurological Manifestation and Deficits

The neurological presentation in these individuals exhibits a range of symptoms, such as ptosis<sup>27</sup>, coma<sup>27</sup>, motor dysfunction<sup>27</sup>, decline in consciousness or unconsciousness<sup>27,29,31,32</sup>, lethargy<sup>31</sup>, somnolence<sup>31</sup>, and dilated but reactive pupils<sup>31</sup>. Other manifestations include speech abnormalities, hemiparesis, aphasia, and in one case, a patient was discharged with persistent hemiplegia. This hemiplegia is a consequence of delayed medical treatment following snakebite envenoming by *Bothrops marajoensis* in Brazil<sup>30</sup>. A case of hemiplegia was also found in the case of patient who was bitten by a *Trimeresurus stejnegeri*<sup>45</sup>. Four days after being bitten, the patient experienced nonfluent aphasia characterized by challenges in both expressing herself and understanding others. In addition, the patient experienced a sudden and severe paralysis **30** on **the right side of** her body<sup>45</sup>.

## CONCLUSION

In conclusion, our scoping review highlights the significant but underrecognized association between hemorrhagic stroke and snakebite envenomation. The findings underscore the diversity in geographical distribution and snake species implicated in these cerebral complications, with Bothrops species identified as a notable contributor in Brazil. Despite the limited number of cases synthesized in this study, the outcomes reveal a spectrum of clinical outcomes ranging from mortality to varying degrees of neurological sequelae. This review underscores the urgent need for heightened awareness, early recognition, and optimized management strategies for hemorrhagic stroke following snakebites, particularly in regions where snakebite-related morbidity and mortality remain a critical public health concern. Further research is warranted to elucidate the underlying pathophysiological mechanisms and establish evidence-based guidelines for the prevention and management of this devastating complication.

## REFERENCES

1. Bagcchi S. Experts call for snakebite to be re-established as a neglected tropical disease. Published online 2015. <https://www.bmj.com/content/351/bmj.h5313.abstract>
2. World Health Organization. (2016). *Guidelines for the Management of Snakebites*. eprints.triatmamulya.ac.id; 2016. [https://eprints.triatmamulya.ac.id/1536/1/Guideline Management for snake bite.pdf](https://eprints.triatmamulya.ac.id/1536/1/Guideline%20Management%20for%20snake%20bite.pdf)
3. Pandey DP, Thapa CL, Hamal PK. Impact of first aid training in management of snake bite victims in Madi valley. *J Nepal Health Res Counc*. 2010;8(1):5-9.
4. David S, Matathia S, Christopher S. Mortality Predictors of Snake Bite Envenomation in Southern India-A Ten-Year Retrospective Audit of 533 Patients. *J Med Toxicol*. 2012;8(2):118-123. doi:10.1007/s13181-011-0204-0
5. Isbister GK. Antivenom availability, delays and use in Australia. *Toxicon X*. 2023;17. doi:10.1016/j.toxcx.2022.100145
6. Stephen E. Meyers; Prasanna Tadi. Snake Toxicity. Published 2022. <https://www.ncbi.nlm.nih.gov/books/NBK557565/>
7. Munawar A, Ali SA, Akrem A, Betzel C. Snake Venom Peptides: Tools of Biodiscovery. *Toxins (Basel)*. 2018;10(11). doi:10.3390/toxins10110474
8. Huang Y-K, Chen Y-C, Liu C-C, Cheng H-C, Tu AT, Chang K-C. Cerebral Complications of Snakebite Envenoming: Case Studies. *Toxins (Basel)*. 2022;14(7). doi:10.3390/toxins14070436
9. Talukdar A, Maddhesiya P, Namsa ND, Doley R. Snake venom toxins targeting the central nervous system. *Toxin Rev*. 2023;42(1):382-406.
10. Dey A, De JN. Traditional use of plants against snakebite in indian subcontinent: A review of the recent literature. *African J Tradit Complement Altern Med*. 2012;9(1). doi:10.4314/ajtcam.v9i1.20
11. Kuch U, Sharma SK, Alirol E, Chappuis F. Fatal neurotoxic envenomation from the bite of a lesser Black Krait (Bungarus Lividus) in Nepal. *Southeast Asian J Trop Med Public Health*. 2011;42(4):960-964. <https://www.scopus.com/inward/record.uri?eid=2-s2.0-80054944243&partnerID=40&md5=772d432e78c86932665d649829caa4f2>
12. Menon JC, Joseph JK. Complications of hemotoxic snakebite in India. In: *Toxinology: Clinical Toxinology in Asia Pacific and Africa*. ; 2015:209-232. doi:10.1007/978-94-007-6386-9\_22
13. Chérifi F, Laraba-Djebari F. Bioactive molecules derived from snake venoms with therapeutic potential for the treatment of thrombo-cardiovascular disorders associated with COVID-19. *Protein J*. Published online 2021:1-43.
14. Ghosh R, León-Ruiz M, Roy D, Naga D, Sardar SS, Benito-León J. Cerebral venous sinus thrombosis following Russell's viper (Daboia russelii) envenomation: A case report and review of the literature. *Toxicon*. 2022;218:8-12. doi:10.1016/j.toxicon.2022.08.014
15. Pérez-Gómez AS, Monteiro WM, João GAP, et al. Hemorrhagic stroke following viper bites and

- delayed antivenom administration: Three case reports from the western Brazilian Amazon. *Rev Soc Bras Med Trop*. 2019;52. doi:10.1590/0037-8682-0115-2019
16. Pinzon RT, Antonius RA, Veronica V. Ischemic Stroke Following *Calloselasma rhodostoma* Snakebite: A Rare Case Report. *Open Access Emerg Med*. 2022;14:35-39. doi:10.2147/OAEM.S352865
  17. Kumar RM, Babu RP, Agrawal A. Multiple infarctions involving cerebral and cerebellar hemispheres following viper bite. *JMS - J Med Soc*. 2015;29(1):51-53. doi:10.4103/0972-4958.158938
  18. Magalhães SF V, Peixoto HM, de Freitas LRS, Monteiro WM, de Oliveira MRF. Snakebites caused by the genera *Bothrops* and *Lachesis* in the Brazilian Amazon: a study of factors associated with severe cases and death. *Rev Soc Bras Med Trop*. 2022;55. doi:10.1590/0037-8682-0558-2021
  19. Del Brutto OH, Del Brutto VJ. Neurological complications of venomous snake bites: A review. *Acta Neurol Scand*. 2012;125(6):363-372. doi:10.1111/j.1600-0404.2011.01593.x
  20. Naik SB. Intravenous snake bite: A catastrophic snake envenomation. *Ann Afr Med*. 2023;22(3):239-245. doi:10.4103/aam.aam\_9\_23
  21. Gasanov SE, Dagda RK, Rael ED. Snake Venom Cytotoxins, Phospholipase A2s, and Zn<sup>2+</sup>-dependent Metalloproteinases: Mechanisms of Action and Pharmacological Relevance. *J Clin Toxicol*. 2014;4(1):1000181.
  22. Resiere D, Mehdaoui H, Neviere R. Inflammation and oxidative stress in snakebite envenomation: a brief descriptive review and clinical implications. *Toxins (Basel)*. 2022;14(11):802.
  23. Larréché S, Chippaux J-P, Chevillard L, et al. Bleeding and thrombosis: Insights into pathophysiology of *Bothrops* venom-related hemostasis disorders. *Int J Mol Sci*. 2021;22(17):9643.
  24. Ranawaka UK, Lalloo DG, de Silva HJ. Neurotoxicity in Snakebite-The Limits of Our Knowledge. *PLoS Negl Trop Dis*. 2013;7(10). doi:10.1371/journal.pntd.0002302
  25. Chaudhary SC, Sawlani KK, Malhotra HS, Singh J. Snake bite-induced leucoencephalopathy. *BMJ Case Rep*. Published online 2013. doi:10.1136/bcr-2012-007515
  26. Ahmed SM, Khan M, Zaka-Ur-Rab Z, Nadeem A, Agarwal S. Hypertensive encephalopathy following snake bite in a child: A diagnostic dilemma. *Indian J Crit Care Med*. 2013;17(2):111-112. doi:10.4103/0972-5229.114819
  27. Dabilgou AA, Sondo A, Dravé A, et al. Hemorrhagic stroke following snake bite in Burkina Faso (West Africa). A case series. *Trop Dis Travel Med vaccines*. 2021;7(1):1-6.
  28. Al-Sadawi M, Mohamadpour M, Zhyvotovska A, et al. Cerebrovascular accident and snake envenomation: a scoping study. *Int J Clin Res trials*. 2019;4.
  29. Hava KA, Mhaili J, Boutakioute B, Idrissi MO, El Ganouni NI. Hemorrhagic stroke revealing a snake bite: A case report. *Cureus*. 2022;14(1).
  30. de Oliveira Pardal PP, da Silva Pinheiro ACJ, Cunha Silva CT, Santos PRSG, da Costa Gadelha MA. Hemorrhagic stroke in children caused by *Bothrops marajoensis* envenoming: A case report. *J Venom Anim Toxins Incl Trop Dis*. 2015;21(1). doi:10.1186/s40409-015-0052-5
  31. Sachett J de AG, Mota da Silva A, Dantas AWCB, et al. Cerebrovascular Accidents Related to Snakebites in the Amazon—Two Case Reports. *Wilderness Environ Med*. 2020;31(3):337-343. doi:https://doi.org/10.1016/j.wem.2020.04.009
  32. Delgado ABT, Gondim CCVL, Reichert LP, et al. Hemorrhagic stroke secondary to *Bothrops* spp. venom: A case report. *Toxicon*. 2017;132:6-8. doi:https://doi.org/10.1016/j.toxicon.2017.03.015
  33. Kumako VK, N'timon B, Apetse K, et al. Two cases of hemorrhagic stroke following Snake bite in Kara teaching Hospital in a Semi Rural Area in Togo. *Sci J Neurol Neurosurg*. 2018;4(1):1-4.
  34. Schneider MC, Min K, Hamrick PN, ... Overview of snakebite in Brazil: Possible drivers and a tool for risk mapping. *PLoS neglected ....* Published online 2021. https://journals.plos.org/plosntds/article?id=10.1371/journal.pntd.0009044
  35. Kini RM, Koh CY. Metalloproteases Affecting Blood Coagulation, Fibrinolysis and Platelet Aggregation from Snake Venoms: Definition and Nomenclature of Interaction Sites. *Toxins (Basel)*. 2016;8(10). doi:10.3390/toxins8100284
  36. Mosquera A, Idrovo LA, Tafur A, Del Brutto OH. Stroke following *Bothrops* spp. snakebite. *Neurology*. 2003;60(10):1577-1580.
  37. Chaves F, Barboza M, Gutiérrez J. Pharmacological study of edema induced by venom of the snake *Bothrops asper* (terciopelo) in mice. *Toxicon*. 1995;33(1):31-39. doi:https://doi.org/10.1016/0041-0101(94)00135-U
  38. Péterfi O, Boda F, Szabó Z, Ferencz E, Bába L. Hypotensive Snake Venom Components-A Mini-Review. *Molecules*. 2019;24(15). doi:10.3390/molecules24152778

39. Sarkar S, Sinha R, Chaudhury AR, et al. Snake bite associated with acute kidney injury. *Pediatr Nephrol.* 2020;36(12):3829-3840. doi:10.1007/s00467-020-04911-x
40. Hou Y-T, Chang M-C, Yang C, et al. Prediction of Compartment Syndrome after Protobothrops mucrosquamatus Snakebite by Diastolic Retrograde Arterial Flow: A Case Report. *Med.* 2022;58(8). doi:10.3390/medicina58080996
41. Rajagopala S, Thabah MM, Ariga KK, Gopalakrishnan M. Acute hypopituitarism complicating Russell's viper envenomation: Case series and systematic review. *QJM.* 2015;108(9):719-728. doi:10.1093/qjmed/hcv011
42. Tsai I-H, Wang Y-M, Cheng AC, et al. cDNA cloning, structural, and functional analyses of venom phospholipases A2 and a Kunitz-type protease inhibitor from steppe viper *Vipera ursinii renardi*. *Toxicon.* 2011;57(2):332-341. doi:https://doi.org/10.1016/j.toxicon.2010.12.012
43. Teixeira C, Fernandes CM, Leiguez E, Chudzinski-Tavassi AM. Inflammation Induced by Platelet-Activating Viperid Snake Venoms: Perspectives on Thromboinflammation. *Front Immunol.* 2019;10. doi:10.3389/fimmu.2019.02082
44. Oliveira AL, Viegas MF, da Silva SL, Soares AM, Ramos MJ, Fernandes PA. The chemistry of snake venom and its medicinal potential. *Nat Rev Chem.* 2022;6(7):451-469. doi:10.1038/s41570-022-00393-7
45. Zeng X, Hu J, Liang X, et al. Acute cerebral infarction following a *Trimeresurus stejnegeri* snakebite: A case report. *Med (United States).* 2019;98(23). doi:10.1097/MD.00000000000015684

